



## CASE REPORT

# Chronic Neuropathic Pain after Umbilical Herniorrhaphy: A Case Report

**María Eugenia Zuluaga Ruiz<sup>1\*</sup>** , **Luz Miriam Leiva Pemberthy<sup>1</sup>** , **Catalina Baena Alvarez<sup>2</sup>**  and **Daniel F. Gallego<sup>3</sup>** 



<sup>1</sup>Department of Physical Medicine and Rehabilitation, Universidad del Valle, Cali, Colombia

<sup>2</sup>Pain and Palliative Care, Department of Physical Medicine and Rehabilitation, Universidad del Valle, Cali, Colombia

<sup>3</sup>Department of Laboratory Medicine and Pathology, University of Washington, Seattle, USA

**\*Corresponding author:** María Eugenia Zuluaga Ruiz, Department of Physical Medicine and Rehabilitation, Universidad del Valle, Calle 4B No 36-140, 760043, Colombia, Tel: +57-2-6206000 Ext. 1541, Fax: 321-2100 Ext 4117

## Abstract

We present the case of a 55-year-old female who recurrently consulted with intense pain in the right periumbilical region. The abdominal cutaneous nerve of root T10 was determined as the affected somatosensory structure and the patient was diagnosed with probable neuropathic pain. A complete history revealed umbilical herniorrhaphy procedure performed 2 years previously and that shortly anteceded the onset of pain. Treatment with 5% topical lidocaine relieved more than 50% of the pain. We discuss the importance of the classification of neuropathic pain and identification of the affected anatomic location with a complete medical history to highlight possible etiologic factors.

## Keywords

Umbilical, Herniorrhaphy, Neuralgia, Lidocaine, Neuropathic pain, Somatosensory disorders

## Introduction

Neuropathic pain is defined as pain arising as a direct consequence of a lesion or disease affecting the somatosensory system [1], with a reported prevalence between 7% and 10% of the general population. It can be classified as central or peripheral. Central neuropathic pain is due to injury or disease of the spinal cord or brain. It includes pain after cerebrovascular accident (stroke) and pain associated with multiple sclerosis [2]. Peripheral neuropathic pain involves injury to small unmyelinated C fibers and myelinated A fibers [3], including conditions such as trigeminal neuralgia, periph-

eral nerve injury, painful polyneuropathy, postherpetic neuralgia, and painful radiculopathy. It is acute when its duration is less than 3 months and chronic when its duration exceeds this time [2].

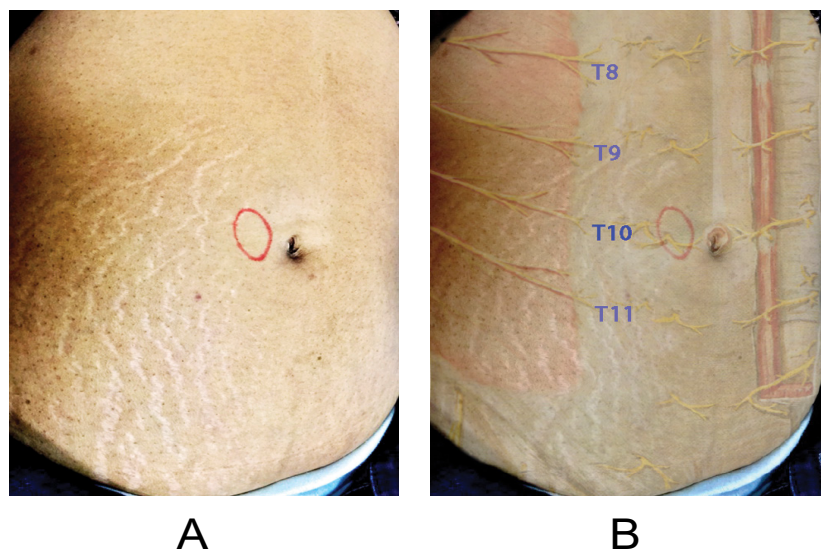
There are three grading criteria for the diagnosis of neuropathic pain according to the International Association for the Study of Pain (IASP) Special Interest Group on Neuropathic Pain (NeuPSIG) [4,5]:

**Possible:** When there is pain with a neuro-anatomically plausible distribution, and a history of a relevant injury or illness affecting the somatosensory system.

**Probable:** When the two conditions above are present plus sensory signs during physical examination in the same neuroanatomically plausible distribution. These signs can include hypoesthesia, hypoalgesia, allodynia, hyperalgesia and temporary summation.

**Definite:** When meets all the three conditions above plus a diagnostic test that confirms the injury or disease underlying neuropathic pain. These are ancillary testing to include imaging, neurophysiology, biopsies, laboratory, etc.

Pain is required to at least be classified as *probable* to offer pharmacological treatment [3].



**Figure 1:** (A) Location of the allodynia area; (B) Distribution of the abdominal cutaneous nerves.

There are several validated tools to detect the presence of neuropathic pain in patients with chronic pain [6] and can be used to alert a clinician to the need for a careful examination in search of neuropathic pain. These are rapid assessment methods, to be used by physicians to include general practitioners, can be self-administered and in the daily practice can help referring patients to the pain specialist.

Two tools have the highest specificity and sensitivity for detecting a neuropathic component in chronic pain. The first one is the Douleur Neuropathique 4 (DN4) questionnaire, which consists of seven items related to symptoms (burning, pain with cold, electric shocks, tingling, needles, numbness and itching) and three items related to the physical examination (hypoesthesia to soft touch, hypoesthesia to pricking and friction-evoked allodynia). This tool is positive with a score greater than four, and has a sensitivity of 85% and a specificity of 80% [7,8]. The second tool is the Pain DETECT, which consists of seven symptom items (burning, tingling or pricking, pain evoked by touch, electric shocks, pain evoked by temperature, numbness and pain evoked by pressure) and two items related to spatial and temporal characteristics. This tool has a sensitivity of 83% and a specificity of 90% [8,9].

Without these objective grading criteria and validated tools, patients with neuropathic pain that cannot be confirmed with ancillary testing (such as electrodiagnostic studies) can potentially be left untreated. We present the case of a patient with chronic neuropathic pain that responded well to therapy after characterizing the affected anatomic structure and determining the underlying etiologic factor.

## Case Report

A 55-year-old female consulted a tertiary center pain clinic manifesting intense pain in the right peri-umbilical

region of two years of evolution. The patient consulted other services to include several general practitioners and psychiatry and was given a course of non-steroidal anti-inflammatory drugs (NSAIDs) without response. The pain was characterized as intense, 9/10 on the visual analogue scale (VAS), it was intermittent, evoked by friction and very localized. The patient was given a marker and asked to draw over her skin the area of pain (Figure 1A). This was a well-defined 2 cm area with allodynia localized in the sensory territory of the terminal branch of the abdominal cutaneous nerve of the T10 root (Figure 1B). The DN4 questionnaire gave a total score of 5/10 (positive by burning, electric shocks, tingling, pins and needles, and pain increased with brushing). An extensive review of the patient's medical history revealed that short after the onset of pain the patient underwent an umbilical herniorrhaphy procedure. The surgeon evaluated the patient during the postoperative period with appropriate reduction of the hernia but did not address possible complaints related to localized pain. Given the absence of any other causal factors, an etiologic nexus was made with the umbilical herniorrhaphy procedure and using the grading criteria from the NeuPSIG a diagnostic of *probable neuropathic pain* was made. Treatment was given with a transdermal lidocaine patch at a concentration of 5% for use 12 hours each day. In a follow-up appointment at four weeks, the patient reported marked improvement of the pain scale with a reduction greater than 50% in VAS (3/10 on the visual analogue scale).

## Discussion

The correct diagnosis of neuropathic pain should be guided by the information in the medical history, the physical examination and the available validated diagnostic questionnaires [8]. One of the most important steps in evaluating neuropathic pain, includes the identification of the affected somatosensory system struc-

ture, which will determine whether it is localized pain or generalized pain. The first-line pharmacological management depends on the site and size of the affected area, and includes 5% lidocaine patch, 8% topical capsaicin, antidepressants and gabapentinoids [10,11].

More than two thirds of patients diagnosed with neuropathic pain obtain insufficient relief, and this is likely related to the inability to target treatment towards the pathophysiological mechanisms that generate the pain [1]. Identifying the underlying etiological factor can help guide the management and the prognosis of patients with pain. One of the common applications of this concept is the lack of response of patients with neuropathic pain to non-steroidal anti-inflammatory drugs (NSAIDs).

In our present case we defined a painful territory innervated by the T10 cutaneous nerve that was assessed according to the International Association for the Study of Pain (IASP) Special Interest Group on Neuropathic Pain (NeuPSIG) grading scale, resulting in a probable neuropathic pain category. A complete medical history revealed the umbilical herniorrhaphy that shortly anteceded the onset of pain. The surgical procedure supported the history of a relevant injury affecting the somatosensory system and during the physical examination it was confirmed a neuroanatomically plausible distribution of the pain. Given all those considerations, topical treatment with lidocaine was initiated. Despite the long period of time without an adequate pharmacological intervention, the patient had a satisfactory response.

The incidence of chronic pain after umbilical or epigastric hernia repair has not been well investigated, but may be 4-20% and possible risk factors for chronic pain remains to be established [12]. In this category of chronic pain, majority of cases are related to recurrence of the hernia; nevertheless, in cases that the hernia is adequately reduced (adequate suture or mesh depending on the surgical approach), underlying causes are not well understood. To our knowledge, there is only one case of neuropathic pain after an umbilical herniorrhaphy reported in literature. This patient had allodynia in the anterior abdominal wall from dermatomes T7 to T12, laterally limited by the anterior axillary line; however, the specific affected somatosensory structure is not described [13]. The therapeutic approach for that case was bilateral block of the *quadratus lumborum* muscle guided by ultrasound in addition to topical capsaicin (8% patch). There was adequate response according to the authors.

Neuropathic pain after inguinal herniorrhaphy is a better characterized and studied entity with multiple case reports of peripheral nerve injury during the surgical procedure [14]. In our case, due to the specific location (an abdominal cutaneous nerve), no electrodiagnostic studies could be performed. This lack of

“diagnostic test that confirms the injury” precludes the diagnosis of definite neuropathic pain by the NeuPSIG definition. The hypothesis of a nerve injury during the umbilical herniorrhaphy is the most feasible explanation after taking in consideration all these factors. The first line treatment of localized neuropathic pain is lidocaine (5%) or capsaicin (8%). Both are equally effective, but due to wide availability in our setting, lidocaine patches were used. Given the rarity of this event, and the lack of available literature, it took two years for the patient to receive a correct diagnosis and treatment.

In conclusion, as noted in the IASP definition, Neuropathic pain is a clinical description (and not a diagnosis) which requires a demonstrable lesion or a disease that satisfies established neurological diagnostic criteria [15]. This case recalls the importance of applying grading criteria for the diagnosis of neuropathic pain when treating a patient with chronic pain and unusual presentation.

## Acknowledgments

MEZ and DFG would like to thank Daniel Augusto for making possible the publication of the present manuscript.

## Conflict of Interest

The authors declare that there is no conflict of interest.

## Funding

There are no financial conflicts of interest to disclose.

## Author Contributions

Luz Miriam Leiva and Maria Eugenia Zuluaga designed the study and wrote the manuscript. Daniel F. Gallego and Catalina Baena contributed to the adjustment of the writing of the article and the review of the literature. All authors have read and approved this manuscript.

There is no relevant financing information.

## References

1. Luana Colloca, Taylor Ludman, Didier Bouhassira, Ralf Baron, Anthony H Dickenson, et al. (2017) Neuropathic pain. *Nat Rev Dis Prim* 3: 17002.
2. Joachim Scholz, Nanna B Finnerup, Nadine Attal, Qasim Aziz, Ralf Baron, et al. (2019) The IASP classification of chronic pain for ICD-11. *Pain* 160: 53-59.
3. JC Watson, P Sandroni (2016) Central Neuropathic pain syndromes. *Mayo Clin Proc* 91: 372-385.
4. Nanna B Finnerup, Simon Haroutounian, Peter Kamerman, Ralf Baron, David LH Bennett, et al. (2016) Neuropathic pain: An updated grading system for research and clinical practice. *Pain* 157: 1599-1606.
5. R-D Treede, TS Jensen, JN Campbell, G Cruccu, JO Dostrovsky, et al. (2008) Neuropathic pain redefinition and a grading system for clinical and research purposes. *Neurology* 70: 1630-1635.

6. FD Eckeli, RA Teixeira, ÁL Gouvêa (2016) Neuropathic pain evaluation tolos. *Rev Dor* 17: 20-22.
7. Concepcion Perez, Rafael Galvez, Silvia Huelbes, Joaquin Insausti, Didier Bouhassira, et al. (2007) Validity and reliability of the Spanish version of the DN4 (Douleur Neuropathique 4 questions) questionnaire for differential diagnosis of pain syndromes associated to a neuropathic or somatic component. *Health Qual. Life Outcomes* 5: 66.
8. D Bouhassira (2019) Neuropathic pain : Definition, assessment and epidemiology. *Rev Neurol (parís)* 175: 16-25.
9. Rainer Freynhagen, Ralf Baron, Ulrich Gockel, Thomas R Tölle (2006) Pain DETECT: A new screening questionnaire to identify neuropathic components in patients with back pain. *Curr Med Res Opin* 22: 1911-1920.
10. NB Finnerup, M Otto, HJ McQuay, TS Jensen, SH Sindrup (2005) Algorithm for neuropathic pain treatment: An evidence based proposal. *Pain* 118: 289-305.
11. Daniel Bates, Carsten Schultheis, Michael C Hanes, Suneil M Jolly, Krishnan V Chakravarthy, et al. (2019) A comprehensive algorithm for management of neuropathic pain. *Pain Med* 20: S1-S12.
12. MM Christoffersen (2015) Clinical outcomes after elective repair for small umbilical and epigastric hernias. *Dan Med J* 62: B5161.
13. Rita Carvalho, Elena Segura, Maria do Céu Loureiro, José Pedro Assunção (2017) Quadratus lumborum block in chronic pain after abdominal hernia repair: case report. *Brazilian J Anesthesiol* 67: 107-109.
14. T Berri (2019) Chronic neuropathic pain following inguinal hernia repair. *Formos J Surg* 52: 111-121.
15. IASP (2020) IASP Terminology.