



IMAGE ARTICLE

A Rare Differential of a Large Abdominal Swelling!

Alhad Mulkalwar*, **Sujay Jaju** and **Jignesh Gandhi**

Department of General Surgery, Seth Gordhandas Sunderdas Medical College and King Edward Memorial Hospital, Mumbai, India



*Corresponding author: Alhad Mulkalwar, Intern (M.B.B.S), Seth Gordhandas Sunderdas Medical College and King Edward Memorial Hospital, Acharya Donde Marg, Parel, Mumbai 400012, India

A 42-year-old male presented with a gradually increasing round abdominal swelling following a blunt trauma to the abdomen 2 weeks back. The swelling was about 5 cm in size when first noticed, which gradually

increased to its present size of around 20 cm (Figure 1). The swelling was accompanied with mild pain and discomfort, which increased with increase in size of the swelling. Clinical examination and radiological

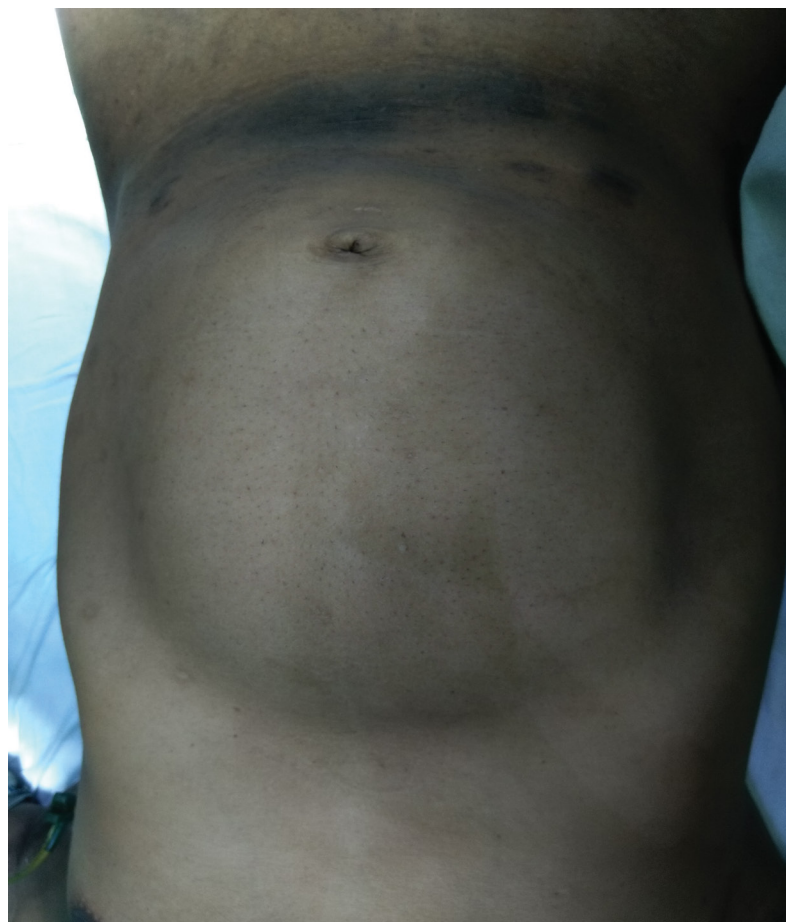


Figure 1: Patient with round abdominal swelling (around 20 cm large).

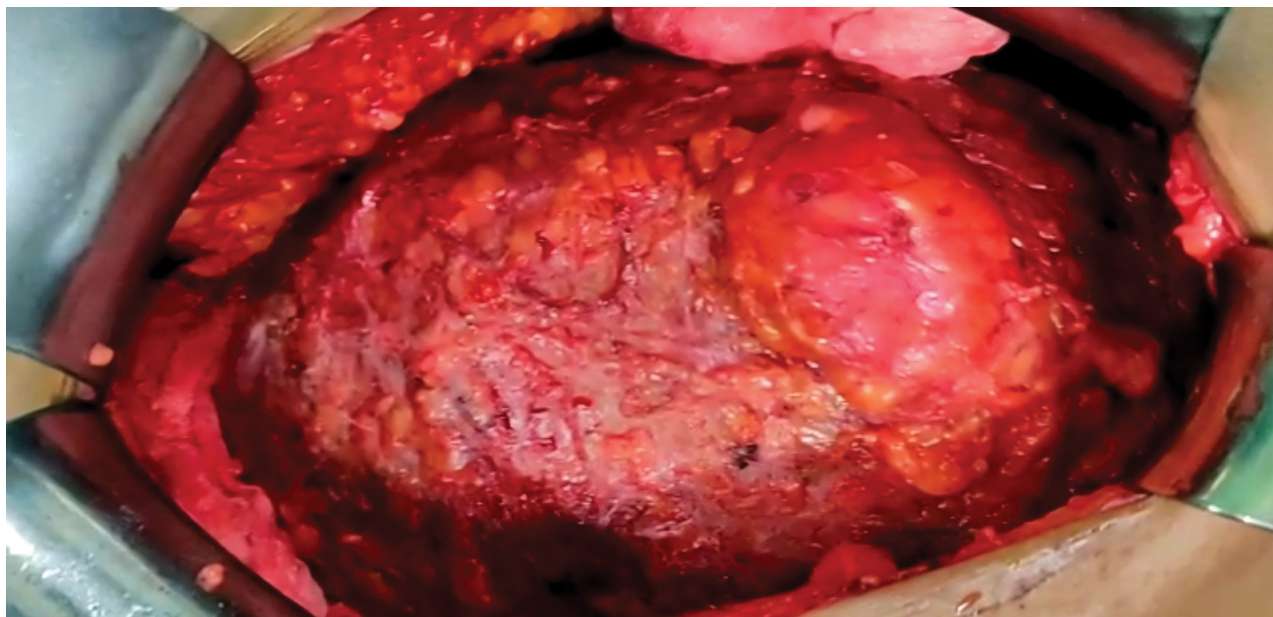


Figure 2: Intra-operative photograph of the seroma.

investigations revealed a large abdominal seroma. Owing to the size of the seroma the patient had to undergo a minor surgical procedure for complete removal of the seroma (Figure 2).

A seroma is a fluid build-up under the surface of the skin. It may develop after a surgical procedure, most

often at the site of the surgical incision or after suffering a blunt trauma as in this case. The fluid may start collecting upto several weeks after the incident. Minor, small seromas don't always need surgical treatment as the fluid would be reabsorbed naturally. Larger ones may require drainage, while very few others may require a surgery for the same.